

# What Do They See & How Do We Know?

## Vision Abnormalities

By Cynthia Cook, DVM, PhD, Dip. ACVO

Photos by author

Last month I described what dogs normally see. So, what kind of eye problems do dogs have and how do you know if your dog's behavior is a result of a vision problem?

Dogs have many of the same eye conditions that people have. The difference is that our dogs can't tell us when their vision has changed and, unless there are other eye symptoms, we may not think of vision as a reason for a change in their behavior. Many of the eye conditions seen most commonly in dogs are inherited and occur with a higher incidence in some breeds of dogs. Many breeds commonly working in agility have a higher incidence of inherited eye disease (see **Table 1**). If your dog is one of these genetically predisposed breeds, annual eye exams are indicated. Eye abnormalities may be present at birth (congenital) or may not occur until 8-10 years of age. Note that congenital abnormalities may or may not be inherited.

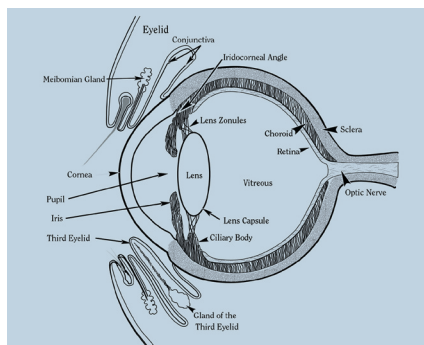


Figure 1: Normal ocular anatomy



## Lens Luxation<sup>1-3</sup>

This genetic condition is caused by a weakness in the small zonule fibers (see **Figure 1**) that support the lens. All terrier breeds are highly predisposed. As the fibers themselves are not visible on a clinical examination, lens instability (lenticulodonesis) is the symptom indicating impending luxation. The lens may remain unstable but not fully luxated (subluxation) for years. Medication may be used to make the pupil small (miosis) and prevent the lens from luxating forward into the anterior chamber. Anterior lens luxation is nearly always associated with acute glaucoma and treatment involves surgical removal of the lens. A replacement lens may or may not be implanted. Without a replacement lens, vision is blurry and probably not adequate for performance work (see **Figure 2**).




Figure 2: Simulation of vision in an eye once the lens has been removed and not replaced. Near vision is affected more than distance vision.

## Cataract<sup>4-6</sup>

A cataract is any clouding of the normal transparent lens in the eye. Although cataracts can be caused by trauma, infectious diseases, or nutritional deficiencies, the vast majority of cataracts are inherited and ultimately affect both eyes. Any breed, including mixed breeds can be affected. Some cataracts remain small and may not significantly affect vision. This is true for one particular type of juvenile cataract seen in the Labrador, Golden Retrievers and the Belgian Tervuren and Shepherd<sup>6</sup>. However, for a performance dog, even minimal degradation of vision (see **Figure 3**) may be enough to affect performance. Cataracts are usually progressive, ultimately resulting in significant vision impairment (see **Figure 4**). In these cases, cataract surgery with implantation of a replacement lens can often restore normal vision. I know of many dogs that have gone on to successfully compete in agility after cataract surgery.




Figure 3: Simulation of vision in an eye with a small, central cataract.




Figure 4: Simulation of vision through a more diffuse cataract. Vision through a mature cataract is like looking through a pane of glass painted white.

# Glaucoma<sup>7</sup>

Glaucoma is a condition associated with elevated pressure within the eye. Inside the eye, fluid (aqueous humor) is produced by the ciliary body. It circulates around the lens and through the pupil into the anterior chamber, where it exits into the bloodstream through a meshwork of tissue located in the iridocorneal angle (see Figure 1). Reduced capacity of the aqueous outflow pathways is the cause of glaucoma. The iridocorneal angle can be directly visualized by looking through a special contact lens applied to the eye (gonioscopy). Normal intraocular pressure is in the range of 10-25 mmHg and is measured by a tonometer, a small pen-like object applied to the eye. Both gonioscopy and tonometry can be performed as part of an examination by an ophthalmologist, without the need for sedation in nearly all cases.

Elevated intraocular pressure can rapidly and irreversibly damage the retina. Pressure elevation greater than 40 mmHg for 24-48 hours is often associated with blindness.

Condition	Age of Onset	Static or Progressive	Prognosis for Vision	Breeds Affected*	Diagnosis
Lens luxation	1-7 years	Usually progressive	Guarded to poor	Terriers, especially Jack Russell Terriers Border Collie <sup>1</sup>	Examination by ophthalmologist
Cataract	0-10 years	Usually progressive	Good with surgery	American Eskimo Australian Cattle Dog Australian Shepherd Bearded Collie Bedlington Terrier Belgian Tervuren Bichon Frise <sup>4</sup> Border Collie Cavalier King Charles Spaniel Cocker Spaniels, American and English Collie Dalmatian Golden Retriever Jack Russell Terrier Labrador Retriever Miniature Schnauzer <sup>28</sup> Nova Scotia Duck Tolling Retriever Papillon Poodle Portuguese Water Dog Shetland Sheepdog, Terriers, Welsh Corgi, Cardigan and Pembroke	Examination by ophthalmologist
Glaucoma	Usually 5-7 years	Progressive	Guarded to poor	Australian Cattle Dog Beagle <sup>29</sup> Bichon Frise Boston Terrier Cocker Spaniel, American and English Dalmatian Jack Russell Terrier Poodle	Examination by ophthalmologist, genetic test
Retinal dysplasia	Congenital	Static, detectable at birth	Mild forms: good Severe forms associated with retinal detachment: poor	English Springer Spaniel <sup>30</sup> Cocker Spaniel, American Golden Retriever <sup>5</sup> Labrador Retriever <sup>31, 32</sup> Samoyed	Examination by ophthalmologist, genetic test
Choroidal hypoplasia/ "Collie eye anomaly"	Congenital	Static, detectable at birth	Most common forms are mild: good	Australian Shepherd <sup>16</sup> Border Collie <sup>33</sup> Collie <sup>11, 13, 34, 37</sup> Nova Scotia Duck Tolling Retriever Shetland Sheepdog <sup>9</sup>	Examination by ophthalmologist, tonometry, gonioscopy
Retinal degeneration				American Eskimo Australian Cattle Dog Australian Shepherd Border Collie Cocker Spaniel, American and English Collie English Springer Spaniel Golden Retriever Labrador Retriever Poodle Portuguese Water Dogs Nova Scotia Duck Tolling Retriever Welsh Corgis, Cardigan and Pembroke	Examination by ophthalmologist, genetic test, electroretinography
Refractive error Myopia Hyperopia Anisometropia		Static, detectable by one year of age	Correctable	All Breeds	Retinoscopy

Table 1: \*This list is not complete. I have listed those breeds commonly represented in agility competition. A more complete listing of affected breeds can be obtained from The Canine Eye Registration Foundation ([www.vmdb.org/cerf.html](http://www.vmdb.org/cerf.html)). CERF also maintains a registry for individual dogs found to be free of known inherited eye conditions. Optigen ([www.optigen.com](http://www.optigen.com)) has genetic tests for eye conditions (PRA/prcd, retinal dysplasia, choroidal hypoplasia) in some breeds.

Although glaucoma is inherited and, often ultimately bilateral, when the first eye is affected, behavior may not be noticeably changed. Dogs can accommodate to having vision in only one eye and, although their depth perception is reduced, it may be difficult to detect behaviorally. Other signs of glaucoma include: cloudiness, redness of the white of the eye, and a dilated pupil. Discomfort is variable. In the acute stage, squinting and obvious signs of pain may be seen. As the condition becomes chronic, affected dogs may behave in a more subdued manner; people with glaucoma describe a headache-like discomfort.

Treatment for glaucoma may involve orally administered medication and topical eye drops, or in some cases, laser surgery. The condition is nearly always progressive and becomes more difficult to control while still preserving vision. Even after vision is lost, the elevated pressure causes discomfort; it is possible to restore comfort using several different surgical procedures.

## Retinal Dysplasia and Choroidal Hypoplasia<sup>8-11</sup>

These two conditions are present at birth, completely static, and in most cases cause minimal impairment of vision. Choroidal hypoplasia is commonly referred to as Collie Eye Anomaly although it is seen in Shelties and Border Collies in addition to rough and smooth Collies.<sup>11-13</sup> Because these conditions are detectable in very young puppies, it is possible to be certain your new performance dog is unaffected. Diagnosis is important to prevent affected or carrier animals from being bred. A more severe form of retinal dysplasia associated with skeletal abnormalities is seen in the Labrador Retriever and Samoyed. The English Springer Spaniel also has a form of retinal dysplasia that covers a spectrum from mild retinal folds to retinal detachment and blindness. Another congenital malformation, Merle Ocular Dysgenesis, affects all of the pigmented structures in the eye in Australian Shepherds homozygous for the merle coat color.<sup>14-16</sup> This condition is associated with a variety of malformations and can result in severe impairment.





Figure 5: Left shows normal dog vision. Right is simulation of vision in a dog with early PRA. Ultimately, affected dogs are completely blind.

## Retinal Degeneration<sup>17-21</sup>

There are many forms of retinal degeneration; collectively they are often referred to as Progressive Retinal Atrophy (PRA). The most common form is progressive rod-cone degeneration (prcd). This condition affects many breeds and is caused by an inherited degeneration of the retinal photoreceptors (rods and cones). As the dog retina consists of primarily rods, a loss of dim light vision is often the first symptom noted (see **Figure 5**). The condition is painless and usually slowly progressive; companion dogs adjust to this handicap extremely well. There are other, less common forms of retinal degeneration, including X-linked PRA in the Siberian Husky<sup>22</sup> and rcd-2, an early onset form of retinal degeneration seen in the Collie.<sup>23</sup> Any breed, including mixed breeds can be affected by PRA. Congenital stationary (nonprogressive) night blindness (CSNB) is seen as an inherited condition in the Briard.<sup>24, 25</sup>

Genetic testing ([www.optigen.com](http://www.optigen.com)) and electroretinography can be used to identify affected dogs long before signs of vision impairment develop and even before abnormalities are detectable by examining the retina during a clinical exam.

## Refractive Errors

As discussed in the previous article, the acuity of the normal dog's eye is much less than we humans have, in large part because of the differences in the retinal cellular communications. Another factor affecting acuity is the ability of the refractive components (cornea, lens) of the eye to bring an object into focus. As in humans, refractive errors in dogs are likely to have a significant genetic component. This has been demonstrated in the Labrador Retriever.<sup>26, 27</sup> The refraction of the eye is assessed using retinoscopy,


an evaluation easily performed by many veterinary ophthalmologists. While abnormalities in refraction probably do not affect the behavior of the companion dog, they may be a significant factor in the function of the performance dog. Dogs with myopia have blurred distance vision (see **Figure 6**); those with hyperopia have blurred near vision (see **Figure 7**) and those with a different refractive error in each eye (anisometropia) have altered depth perception. These refractive errors can be corrected using contact lenses. However, it is important to recognize that vision is only one of the many reasons our dogs behave



Figure 6: Simulation of vision in a dog with myopia.






Figure 7: Simulation of vision in a dog with hyperopia.



### Get Started With Our 4-Jump Kit

includes all necessary pipe, fittings and jump cups to build 4 jumps that adjust from 3" to 35" in height

# All the PVC You Need to Build It Yourself

## PatiosToGo.com

### 352.243.3220

Furniture Grade PVC  
Low Minimum Order • Box Quantity Discounts

*vinyl tape for striping too!*

the way they do. If your dog's behavior suggests a vision problem (knocked bars, missed weave pole entries), his vision should be checked by an ophthalmologist. If a refractive error of greater than 2 D is detected, it may be a contributing factor, but for a dog that has lived and trained for years with the vision he is accustomed to, correcting it may or may not significantly improve his performance.

## Final Thoughts

When should your dog be examined by an ophthalmologist?

- At 3 to 4 months of age, particularly if the breed is predisposed to congenital eye conditions; at one year for other breeds, annually thereafter
- Following a known injury or sudden onset of pain (squinting, copious tearing, rubbing at the eye); this should be considered urgent
- A change in appearance of the eye(s): cloudiness, change in color
- Swelling/enlargement of the eye
- Change in vision; if sudden in onset, this would be considered urgent

- Unequal pupil size or lack of response to light
- Redness and/or mild tearing are considered less significant in the absence of signs of discomfort or a noticeable change in the appearance of the eye

As a final word of caution, don't let your dog hang his head out the car window. Even small particulate objects flying toward him at 60 mph can easily injure the eyes. Carry a bottle of eye wash (for humans, available in drugstores) and irrigate your dog's eyes to remove debris following a trip to the beach or a hike, before your dog has a chance to rub the eye and create an injury. 🐕

Cynthia Cook, DVM, PhD, Dip. ACVO, is the founder of Veterinary Vision, with offices in San Carlos, and San Francisco, California, and a staff of three other veterinary ophthalmologists. Besides her clinical practice, she is active in lecturing, research, and consulting activities in academia and industry. Dr. Cook is also an agility enthusiast. More information about animal vision and eye diseases is available at [www.VeterinaryVision.com](http://www.VeterinaryVision.com).

### References

- 1 Foster, Curtis, and Barnett, *Primary Lens Luxation in the Border Collie*. Journal of Small Animal Practice, 1986. **27**: p. 1.

2 Curtis, R. and K.C. Barnett, *Primary lens luxation in the dog*. J Small Anim Pract, 1980. **21**(12): p. 657-68.

3 Curtis, R., *Lens luxation in the dog and cat*. Vet Clin North Am Small Anim Pract, 1990. **20**(3): p. 755-73.

4 Wallace, M.R., et al., *Inheritance of cataract in the Bichon Frise*. Vet Ophthalmol, 2005. **8**(3): p. 203-5.

5 Gelatt, D., *Animal Models for Inherited Cataracts: A Review*. Experimental Eye Research, 1984. **3**: p. 765.

6 Curtis, R. and K.C. Barnett, *A survey of cataracts in golden and labrador retrievers*. Journal of Small Animal Practice, 1989. **30**: p. 277-289.

7 Gelatt, K.N. and E.O. MacKay, *Prevalence of the breed-related glaucomas in pure-bred dogs in North America*. Vet Ophthalmol, 2004. **7**(2): p. 97-111.

8 Long, S.E. and S.M. Crispin, *Inheritance of multifocal retinal dysplasia in the golden retriever in the UK*. Vet Rec, 1999. **145**(24): p. 702-4.

9 Barnett, K. and F. Stades, *Collie eye anomaly in the Shetland Sheepdog in the Netherlands*. Journal of Small Animal Practice, 1979. **20**: p. 321.

10 Bedford, P., *Collie eye anomaly in the United Kingdom*. Veterinary Record, 1982. **111**: p. 263.

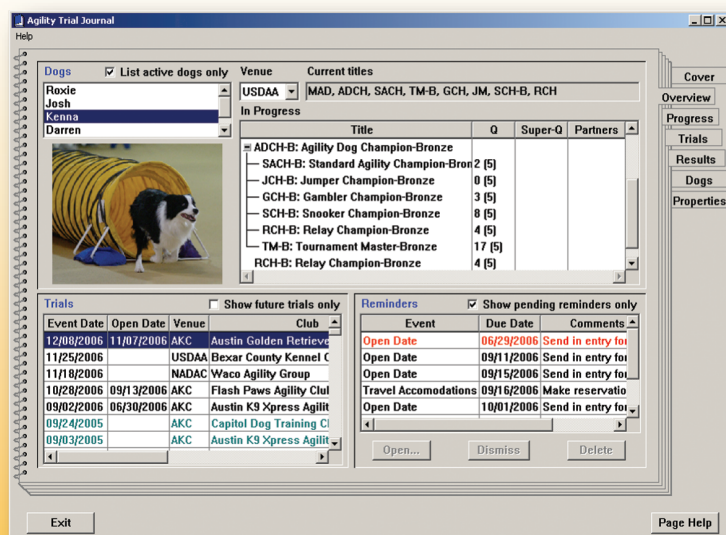
11 Lowe, J.K., et al., *Linkage mapping of the primary disease locus for collie eye anomaly*. Genomics, 2003. **82**(1): p. 86-95.

12 Gelatt, K., N. Powell, and K. Huston, *Inheritance of microphthalmia with coloboma*

*Earning titles is difficult.*

*Keeping track of them doesn't have to be!*

## Agility Trial Journal®



- Easy to use notebook tabs
- Multiple venue support
- Built in rules track titles and points
- Analyze performance
- Enter trial information, set reminders
- Record results, placements, issues, and performance notes
- Tutorial, Help, and User Guide included

Download your *free*  
30-day evaluation  
copy today!



**Flat Creek Studios, Inc.**  
[www.FlatCreekStudios.com](http://www.FlatCreekStudios.com)  
[Sales@FlatCreekStudios.com](mailto:Sales@FlatCreekStudios.com)

Copyright © 2004-2006



in the Australian shepherd dog. American Journal of Veterinary Research, 1981. **42**(10): p. 1686-1690.

13 Rubin, L., E. Nelson, and C. Sharp, *Collie eye anomaly in Australian shepherd dogs*. Progress in Veterinary and Comparative Ophthalmology, 1991. **1**(2): p. 105-108.

14 Bertram, T., F. Coignoul, and N. Cheville, *Ocular dysgenesis in Australian shepherd dogs*. Journal of the American Animal Hospital Association, 1984. **20**: p. 177.

15 Cook, C., K. Burling, and E. Nelson, *Embryogenesis of posterior segment colobomas in the Australian shepherd dog*. Progress in Veterinary & Comparative Ophthalmology, 1991.

16 Munyard, K.A., C.R. Sherry, and L. Sherry, A retrospective evaluation of congenital ocular defects in Australian Shepherd dogs in Australia. Veterinary ophthalmology, 2007. **10**(1): p. 19-22.

17 Millichamp, N.J., *Retinal degeneration in the dog and cat*. Veterinary Clinics of North America. Small Animal Practice, 1990. **20**(3): p. 799-835.

18 Ray, K., et al., Molecular diagnostic tests for ascertainment of genotype at the rod cone dysplasia 1 (rcd1) locus in Irish setters. Curr Eye Res, 1995. **14**(3): p. 243-7.

19 Clements, P.J., et al., Recent advances in understanding the spectrum of canine generalised progressive retinal atrophy. J Small Anim Pract, 1996. **37**(4): p. 155-62.

20 Lin, C.T., et al., Canine inherited retinal degenerations: update on molecular genetic

research and its clinical application. J Small Anim Pract, 2002. **43**(10): p. 426-32.

21 Petersen-Jones, S., *Advances in the molecular understanding of canine retinal diseases*. J Small Anim Pract, 2005. **46**(8): p. 371-80.

22 Acland, G., et al., XL-PRA: An X-linked form of progressive retinal atrophy in Siberian Husky dogs. Proc Proceedings of the American College of Veterinary Ophthalmology, 1993. **24**: p. 37.

23 Acland, G.M., et al., Non-allelism of three genes (rcd1, rcd2 and erd) for early-onset hereditary retinal degeneration. Experimental Eye Research, 1989. **49**(6): p. 983-98.

24 Aguirre, G.D., et al., Congenital stationary night blindness in the dog: common mutation in the RPE65 gene indicates founder effect. Mol Vis, 1998. **4**: p. 23.

25 Narfstrom, K., Retinal dystrophy or 'congenital stationary night blindness' in the Briard dog. Vet Ophthalmol, 1999. **2**(1): p. 75-76.

26 Mutti, D.O., K. Zadnik, and C.J. Murphy, *Naturally occurring vitreous chamber-based myopia in the Labrador retriever*. Invest Ophthalmol Vis Sci, 1999. **40**(7): p. 1577-84.

27 Black, J.M., et al., A canine model of inherited myopia: Familial aggregation of refractive error in Labrador Retrievers. Investigative ophthalmology & visual science, 2008.

28 Zhang, R.L., et al., *Analysis of eye lens-specific genes in congenital hereditary cataracts and microphthalmia of the miniature schnauzer dog*. Invest Ophthalmol Vis Sci, 1991. **32**(9): p. 2662-5.

29 Gelatt, K., *Clinical manifestations of*

*inherited glaucoma in the Beagle*. Investigative Ophthalmology and Visual Science, 1977. **16**: p. 1135.

30 O'Toole, D., et al., Retinal dysplasia of English springer spaniel dogs: Light microscopy of the postnatal lesions. Vet Pathol, 1983. **20**: p. 298-311.

31 Barnett, K., G. Bjorck, and E. Kock, *Hereditary retinal dysplasia in the labrador retriever in England and Sweden*. J Small Anim Pract, 1970. **10**: p. 755-759.

32 Nelson, D. and A. MacMillan, *Multifocal retinal dysplasia in field trial Labrador retrievers*. J Am Anim Hosp Assoc, 1983. **19**: p. 388-392.

33 Bedford, P., *Collie eye anomaly in the Border Collie*. Veterinary Record, 1982. **111**: p. 34.

34 Wallin-Hakanson, B., N. Wallin-Hakanson, and A. Hedhammar, Influence of selective breeding on the prevalence of chorioretinal dysplasia and coloboma in the rough collie in Sweden. J Small Anim Pract, 2000. **41**(2): p. 56-59.

35 Wallin-Hakanson, B., N. Wallin-Hakanson, and A. Hedhammar, *Collie eye anomaly in the rough collie in Sweden: genetic transmission and influence on offspring vitality*. J Small Anim Pract, 2000. **41**(6): p. 254-258.

36 Donovan, E. and M. Wyman, *Ocular fundus anomaly in the Collie*. Journal of the American Veterinary Medical Association, 1965. **147**: p. 1465-1469.

37 Sargan, D.R., *Collie eye anomaly in the rough collie*. J Small Anim Pract, 2001. **42**(4): p. 204.

Your dogs will love you for it!

## Top Dog Flooring for Dog Agility, Training, Daycare, Shows

TRAC-ROLL offers a solution to working dogs on unforgiving cement by providing an attractive, durable, easily maintained, and non-slip cushioned surface.

- Excellent traction wet or dry
- Made of recycled tire rubber
- 4' wide, any length, 8MM thick
- Easy to clean, just mop and go

Call or write today for your free sample.

**Dandy Products, Inc.**

3314 State Route 131, Goshen, Ohio 45122  
(513) 625-3000 ■ [www.dandyproducts.net](http://www.dandyproducts.net)

Top Dog Flooring at  
BRAG Training Center  
Columbus, Ohio

Photo by Marie Ewing,  
Paws the Moment Photography

Available in black with  
10% blue or grey color  
fleck or in black with  
20% multi-color fleck